

CHEST[®]

Official publication of the American College of Chest Physicians



Shark oil pneumonia. An overlooked entity

DS Asnis, HP Saltzman and A Melchert

Chest 1993;103;976-977

The online version of this article, along with updated information and services can be found online on the World Wide Web at:
<http://chestjournals.org/cgi/content/abstract/103/3/976>

CHEST is the official journal of the American College of Chest Physicians. It has been published monthly since 1935. Copyright 2007 by the American College of Chest Physicians, 3300 Dundee Road, Northbrook IL 60062. All rights reserved. No part of this article or PDF may be reproduced or distributed without the prior written permission of the copyright holder (<http://www.chestjournal.org/misc/reprints.shtml>). ISSN: 0012-3692.

A M E R I C A N C O L L E G E O F



C H E S T

P H Y S I C I A N S[®]

Shark Oil Pneumonia*

An Overlooked Entity

Deborah S. Asnis, M.D.;† Herbert P. Saltzman, M.D., F.C.C.P.;‡
and Alex Melchert, M.S.§

Nonprescription drugs are often believed to be innocuous. We present a case of lipoid pneumonia from ingestion of squalene, a derivative of shark liver oil, a popular over-the-counter Asian folk remedy. (*Chest* 1993; 103:976-77)

Lipoid pneumonia has been recognized since the early 20th century as a disease process in the lung related to the abnormal presence of organic or inorganic lipids.¹ The first case was described in 1925 by Laughlin.² An incidence of 2 to 5 percent was found in one autopsy study.³ To our knowledge, the case presented is the first description of a severe exogenous lipoid pneumonia by means of aspiration of squalene, derived from shark liver oil. The capsules are readily available in Asian health food stores. Squalene is also used widely in cosmetics.

CASE REPORT

A 46-year-old hypertensive Korean man was admitted to Flushing Hospital complaining of three days of progressive left facial and extremity weakness. He denied taking any medications.

On physical examination, the only abnormal finding was a dense left hemiplegia with a left central facial nerve paralysis.

Laboratory studies at the time of hospital admission included a normal complete blood cell count, electrolytes, and urinalysis. The aspartate aminotransferase was 67 U/L, alanine aminotransferase was 120 U/L, γ -glutamyl transpeptidase was 129 U/L and lactate dehydrogenase was 263 U/L. Hepatitis profile was negative. Electrocardiogram suggested old inferior wall infarction and chest roentgenogram was normal. A computed tomographic (CT) scan of the head revealed bilateral basal ganglia infarcts, and sinus views were normal. Liver sonography showed fatty infiltration.

On day 3, he developed singultus requiring chlorpromazine (Thorazine). On day 6, the temperature was 38.4°C. Intravenous (IV) cefazolin therapy was started after a repeat chest roentgenogram showed extensive left perihilar infiltrate and minimal right perihilar consolidation (Fig 1). Arterial blood gas determination on 35 percent oxygen was a pH of 7.44, P_{CO_2} of 35 mm Hg, HCO_3^- of 23 mmol/L, and oxygen saturation of 97 percent. All blood and urine cultures were negative. Sputum Gram stain showed leukocytes with mixed flora and cultured only yeast. The patient continued to spike fever and maximal leukocyte count was 16,500/cu mm. Vancomycin, ceftazidime, and erythromycin were substituted for cefazolin. A CT scan of the chest revealed left upper and lower lobe and right lower lobe consolidation. Cold agglutinins, *Legionella*, and *Mycoplasma* titers, and serum precipitins were negative.

Fiberoptic bronchoscopy was performed on day 24 and all smears and cultures, including routine, mycobacterial, *Legionella*, *Mycoplasma*, and viral studies were negative on bronchoalveolar lavage fluid (BAL). Cytologic examination of BAL fluid revealed abundant

*From the Departments of Internal Medicine (Drs. Asnis and Saltzman) and Pharmacy (Mr. Melchert), Flushing Hospital Medical Center, Affiliate of the Albert Einstein College of Medicine, Flushing, NY.

†Associate Director of Infectious Diseases.

‡Director of Pulmonary Medicine and Associate Director of Critical Care Medicine.

§Associate Director of Pharmacy.

Reprint requests: Dr. Asnis, Flushing Hospital and Medical Center, 4500 Parsons Blvd, Flushing, NY 11355

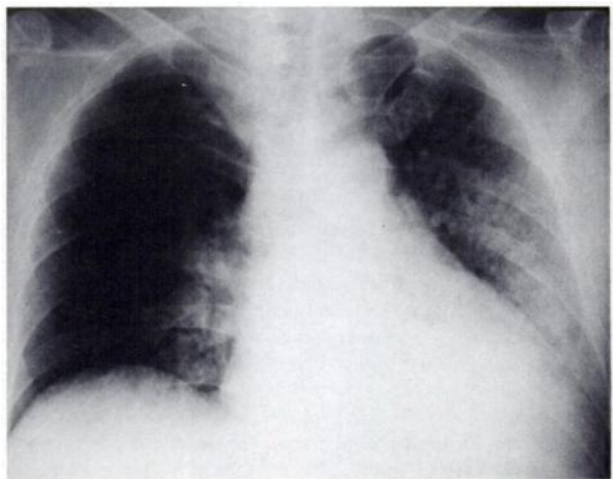


FIGURE 1. Chest roentgenogram. Extensive left perihilar infiltrate and minimal right perihilar consolidation.

lipid-filled macrophages (Fig 2). Transbronchial biopsy specimens from the left lower lobe showed marked fibrous connective tissue proliferation with aggregation of histiocytes simulating granulomas and lipid-laden macrophages. Special stains were negative.

Antibiotic therapy was stopped and steroid therapy was begun. He defervesced with slight regression in the pulmonary infiltrates. After repeated questioning, it was discovered that he had taken 10 squalene capsules per day for the past year and that during hospitalization, his wife had been feeding him multiple capsules daily as a cure for hiccoughs and without the knowledge of the medical staff.

DISCUSSION

Lipoid pneumonia is divided into endogenous and exogenous forms. In the case of endogenous (cholesterol) pneumonia, the fatty materials are derived from the lung itself as in malignant obstructing bronchial tumors or bronchiectasis. In the more commonplace exogenous lipoid pneumonia, lipids enter the lung parenchyma as a result of aspiration.³ The effects on the lung are primarily related to the content of fatty acid: vegetable oils such as poppyseed and sesame produce little if any pulmonary parenchymal damage vs chaulmoogra oil, which is rich in fatty acids. Mineral oil is fairly inert and causes an influx of phagocytizing alveolar macrophages with an accompanying infiltrate within several

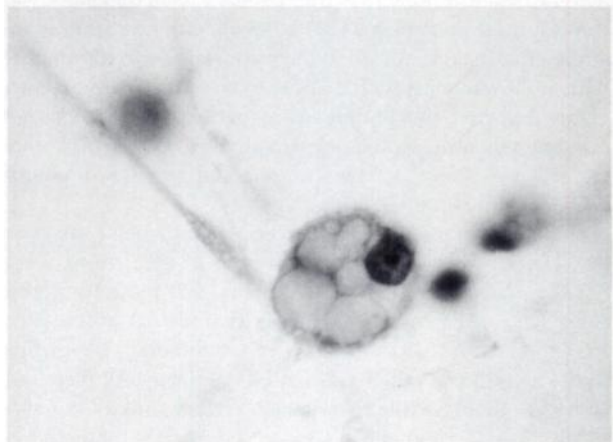


FIGURE 2. Cytologic specimen; lipid-laden macrophage (original magnification, $\times 250$).

days and granulomas with fibrosis in two to three months.^{3,4} Animal fats produce the most injury to the lung when aspirated because of their high fatty acid content.^{3,4} Those described previously include milk fat, lard oil, rabbit fat, and cod liver oil.

Conditions associated with lipoid pneumonia include debilitated patients with achalasia, esophageal diverticulum, neurologic diseases, or altered mental status. Extremes of age are favored.³ The typical presentation is a patient with a chronic cough or an asymptomatic patient with incidental chest roentgenographic findings. On chest roentgenogram, either a diffuse multilobar infiltrate or a circumscribed lower lobe infiltrate develops.¹ The diagnosis is made by sputum examination for fat with sudan IV stain. Macrophages with orange-brown vacuoles will be found in 90 to 95 percent. Bronchial washings, transbronchial biopsies, or open lung biopsies are occasionally needed. The treatment is to terminate the offending agent. Antibiotics are given if there is a superimposed infection. In severely ill patients, prednisone 40 to 60 mg is helpful and dosage is tapered over a month.³ Surgery is performed if concurrent malignancy is suspected.

In our case, the patient ingested squalene for one year and had abnormal liver function. Squalene fed to dogs in doses of 1,200 mg/kg orally accumulated 6 percent of the

daily dose in their livers without toxic signs or enzyme abnormalities.³ Our experience suggests that hepatic squalene accumulation may be more toxic in humans than animal studies would have predicted.

It is proposed that the medical community be aware of the widespread use of squalene in Oriental communities and of its capacity to produce a marked exogenous lipoid pneumonia and possibly liver toxicity as well.

ACKNOWLEDGMENTS: We would like to thank Mr. Jack Rush, BPA, our photographer, and Dr. Nak Chin Chung for his kind referral.

REFERENCES

- 1 Sundberg RH, Kirschner KE, Brown MJ. Evaluation of lipoid pneumonia. *Dis Chest* 1959; 36:594-601
- 2 Laughlin GF. Studies of pneumonia following naso-pharyngeal injections of oil. *Am J Pathol* 1925; 1:407-14
- 3 Bartlett JG. Lipoid pneumonia. In: Baum GL, Wolinsky E, eds. *Textbook of pulmonary diseases*. Boston: Little Brown & Co, 1989:557-63
- 4 Pinkerton H. The reaction of oils and fats in the lung. *Arch Pathol Lab Med* 1928; 5:380-401
- 5 Kamimura H, Koga N, Oguri K, Yoshimura H, Inoue H, Sato K, et al. Studies on distribution, excretion and subacute toxicity of squalene in dogs. *Fukuoka Igaku Zasshi* 1989; 80:269-80

Shark oil pneumonia. An overlooked entity
DS Asnis, HP Saltzman and A Melchert
Chest 1993;103;976-977

This information is current as of April 17, 2007

Updated Information & Services	Updated information and services, including high-resolution figures, can be found at: http://chestjournals.org
Citations	This article has been cited by 2 HighWire-hosted articles: http://chestjournals.org
Permissions & Licensing	Information about reproducing this article in parts (figures, tables) or in its entirety can be found online at: http://chestjournals.org/misc/reprints.shtml
Reprints	Information about ordering reprints can be found online: http://chestjournals.org/misc/reprints.shtml
Email alerting service	Receive free email alerts when new articles cite this article sign up in the box at the top right corner of the online article.
Images in PowerPoint format	Figures that appear in CHEST articles can be downloaded for teaching purposes in PowerPoint slide format. See any online article figure for directions.

A M E R I C A N C O L L E G E O F



P H Y S I C I A N S[®]